

# EMR

The Electronic Medical Record in its entirety can be found on pages 39-54. The EMR is the reading tool that students will use as they complete *The Virtual Stroke Lab*. The idea of the EMR was that students only have to read what they need, at the moment they need it. This version of the EMR is in alphabetical order, not the order in which students will come into contact with it while completed *The Virtual Stroke Lab*.

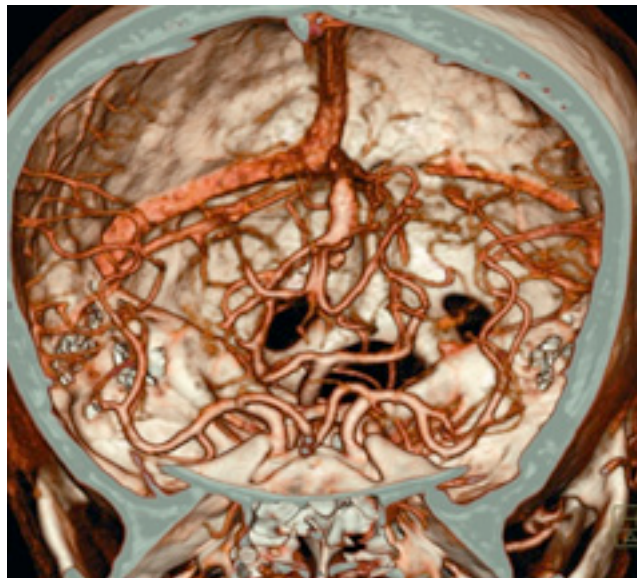The philosophy of the MIND project is that students shouldn't memorize rote facts, but be able to make sense of the information when exposed to it in a real-life situation/simulation. The EMR is organized to reflect this philosophy. When students click on the EMR button in the Main Menu, the information is organized by question. Only the questions they need to answer are available to them. So at the beginning of the lab, there are fewer questions than at the time they complete the lab. Students can refer to any past question, even after they initially read the material.

It is up to you as the teacher whether or not you want to test students on details in the EMR. However, the lab was designed so that the experience of doing the simulated lab could be sufficient as a stand-alone activity.

## 3D CT ANGIOGRAPHY (3D CTA)

---

Iodinated contrast is injected through a small peripheral vein, usually in the arm. The dye flows through the body and is imaged as it passes through the brain. These images can be used to create a computer generated 3D model of blood vessels in the brain.



3D CT Angiogram

## 3D ROTATIONAL DSA

---

3D Rotational DSA is very similar to regular DSA, except that the fluoroscopy machine is rotated around the patient while scanning. The 3D Rotational DSA series of images are used to create a 3D model of blood vessels in the brain.

## ANEURYSM

---

An aneurysm is a permanent ballooning in the wall of an artery. The pressure of blood passing through can force part of a weakened artery to bulge outward, forming a thin-skinned blister or sac. The gravest threat an aneurysm poses is that it will burst and cause a stroke or life-threatening hemorrhage. Even if it doesn't rupture, a large aneurysm can impede circulation and promote

unwanted blood-clot formation.



Saccular Aneurysm



Fusiform Aneurysm



Ruptured Aneurysm

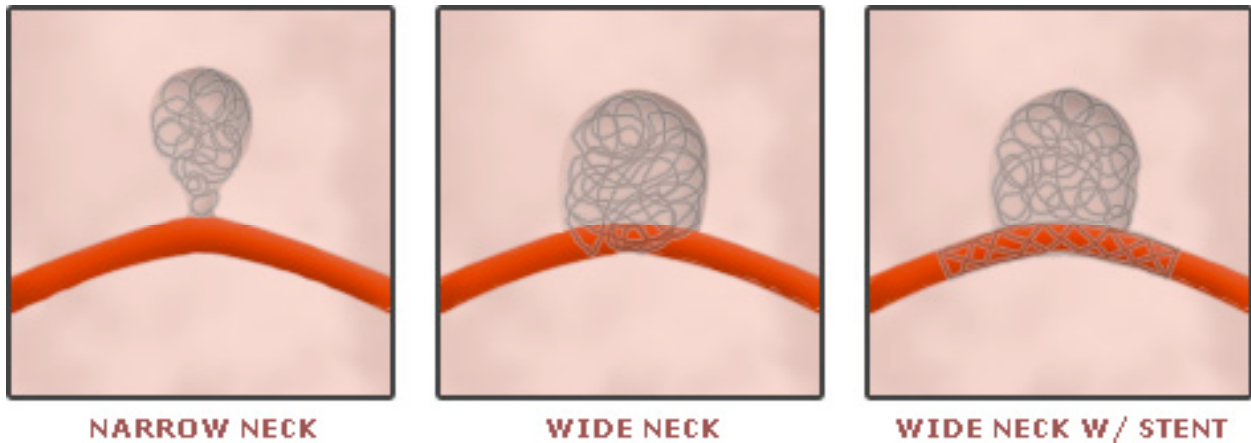### Types of Aneurysms

#### TYPES OF ANEURYSMS

Any condition that causes arterial walls to weaken or deteriorate can result in an aneurysm. The most common culprits are Atherosclerosis and high blood pressure. Penetrating wounds and infections can also lead to an aneurysm. Some types, such as Berry Aneurysms, are the result of congenital, or inherited, weakness in artery walls.

## ANEURYSM NECK SIZE

---



### Aneurysm Shapes

\* A neck of greater than 4 mm will allow the coils to loop out of the aneurysm. This will cause blood clots to form within the brain blood vessel, resulting in a stroke.

\* A narrow-neck aneurysm will prevent coils from looping out into the brain blood vessels.

\* Wide neck aneurysms can be treated with coils if a balloon or stent is placed in the brain vessel.

## ANEURYSM TREATMENT OPTIONS

---

### Coiling

- Performed in a neuroendovascular suite by a neuroendovascular radiologist or surgeon.
- Minimally invasive procedure without surgical cutting through to the brain blood vessels.
- A catheter is navigated through a vessel in the groin region and advanced to the aneurysm using fluoroscopy.
- Platinum coils attached to a delivery wire are deployed through catheter into the aneurysm. The wire is detached and removed, leaving the coil within the aneurysm. A number of coils are needed to occlude the aneurysm.

## Clipping

- A craniotomy (surgical drilling and cutting to create a window through the skull) is performed. The brain is retracted to locate the aneurysm.
- A small clip is placed across the neck (or "opening") of the aneurysm to block normal blood flow from entering.
- The clip remains on the artery permanently.

## Should an Aneurysm be Clipped or Coiled?

- Studies have shown that patients with ruptured and unruptured aneurysms have better clinical outcomes from coiling rather than clipping. There is less recovery time required and no manipulation of brain tissue.
- Surgical clipping is still used for younger patients with superficial, easy-to-access aneurysms.
- The size and morphology (or shape) of an aneurysm is extremely important when determining whether to coil or clip.
- The overall risk rate for both procedures is comparable.
- The advantage of surgical clipping is that it is almost always permanent.
- The disadvantage of coiling is that the coils may compact within the aneurysm and may require retreatments. This is mostly dependent on the size of the aneurysm.

## COILING COMPLICATIONS

---

The aneurysm can rupture if the microcatheter or wire penetrates through the wall.

Coils can loop out of the aneurysm if not placed carefully. This can cause blockage of brain blood vessels, resulting in an ischemic stroke.

Clots may form on the devices used and may also cause ischemic strokes. This is why medication is given at the beginning of coiling to prevent blood clots.

## CT SCAN

---

An X-ray beam is rotated around the head to create an image slice of the brain, called "computerized tomography". Sometimes iodinated contrast is administered through a vein in the arm. This dye flows throughout the body and is imaged once it reaches the brain. Iodinated contrast, like bone, absorbs energy and will appear on the scan results.

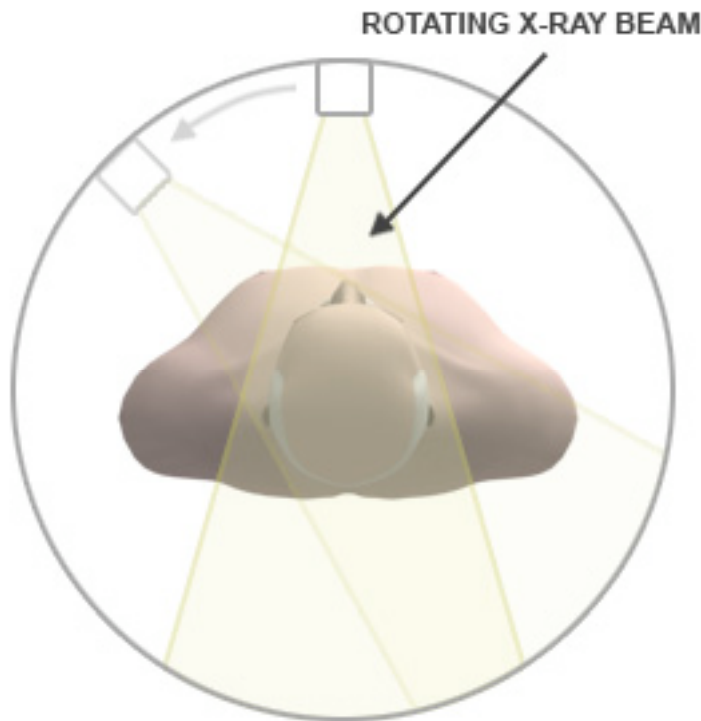
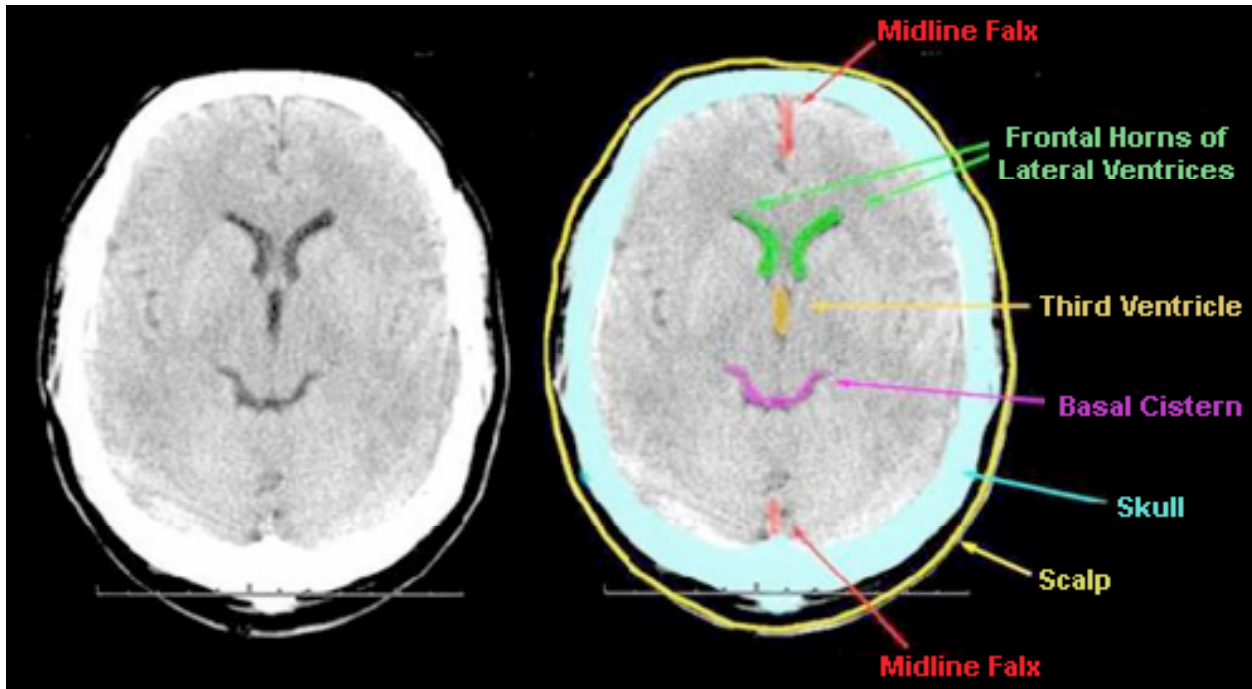


ILLUSTRATION OF X-RAY BEAM ROTATING AROUND PATIENT

## CT SCANS (INTERPRETING)

---

Reading a CT Scan can be tricky and involves an immense amount of training. CT Scans are black and white and the coloration is very dependent upon density. More dense areas appear lighter while less dense areas appear darker. So, dark spaces on a CT Scan indicate empty space while white spaces often indicate dense objects. In the brain, most tissue will normally appear gray, with empty spots (such as the ventricles), appearing black. The skull and other bones will appear white. Such an example can be seen below:

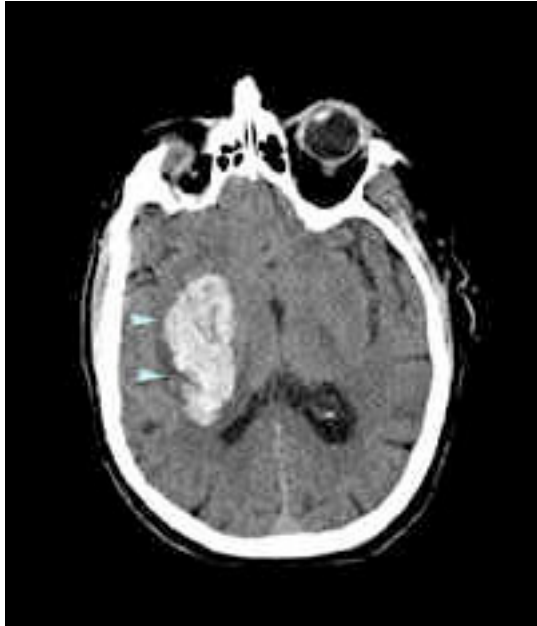

CT SCAN W/ LABELS ILLUSTRATING THE EFFECTS OF MATERIAL DENSITY

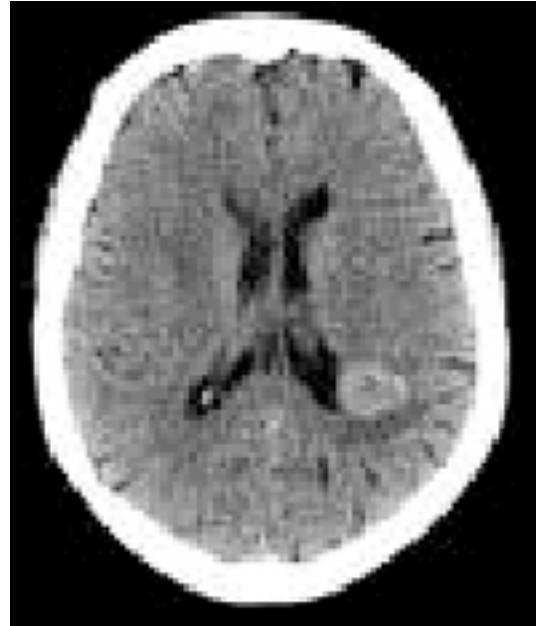Radiologists reading CT Scans normally look for abnormalities in tissue to give them diagnostic clues. In the CT Scan below on the left, you can see a large white mass in the normally gray brain tissue. This is an indication of bleeding the brain, caused in this case by an arteriovenous malformation (AVM).

The CT Scan on the right shows a small mass in the lower right hand quadrant. While still gray, it is lighter than the surrounding tissues, indicating a denser area. In this case, this is a brain tumor:

## CT Scan w/ Bleeding



THE WHITE PATCH IN THIS  
CT SCAN INDICATES BLEEDING

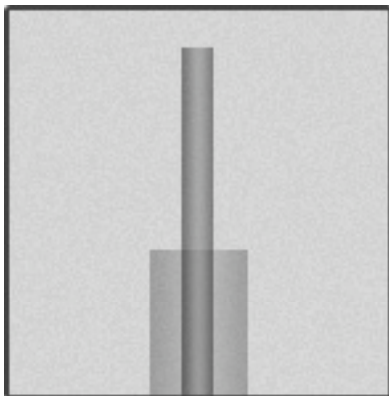


THE GRAY SPOT IN THIS  
CT SCAN INDICATES A TUMOR


## DIGITAL ROAD MAPPING

---

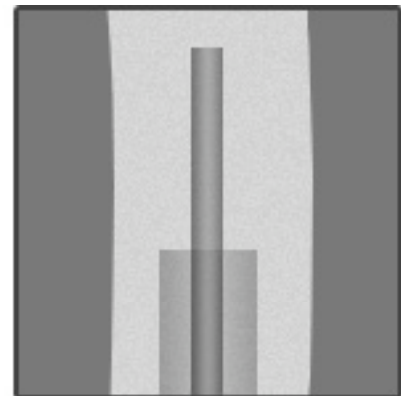
A digital road map is a process by which wires and catheters are navigated through blood vessels of the brain. The DSA image depicting the artery is superimposed on a live fluoroscopic x-ray image.



**LIVE FLUOROSCOPIC  
VIDEO ONLY SHOWS  
HARD-BODIED OBJECTS,  
SUCH AS THE CATHETER  
AND COIL SEEN HERE.**



**BY SCANNING THE  
ARTERIES WHILE THEY  
ARE FILLED WITH  
CONTRAST DYE, THEIR  
SHAPE CAN THEN BE  
VISUALIZED.**



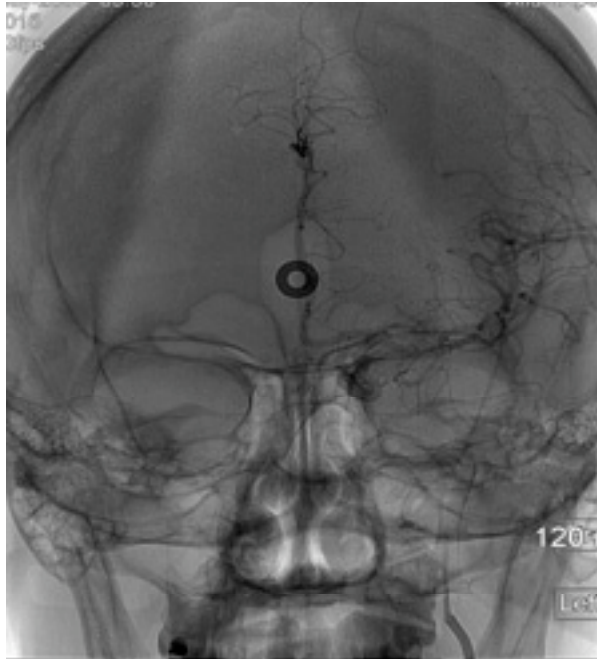**THE ARTERY IMAGES CAN  
THEN BE PLACED OVER  
THE LIVE VIEW AND  
USED AS A MAP.**



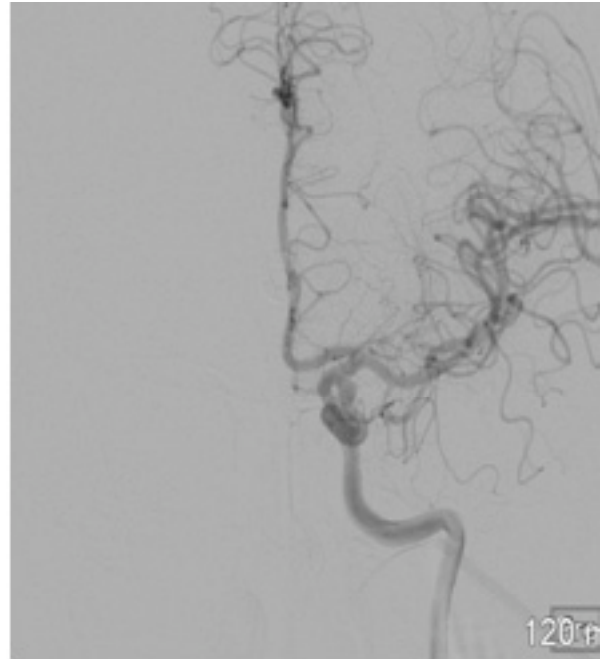
## DIGITAL SUBTRACTION ANGIOGRAPHY (DSA)

---

Digital Subtraction Angiography (DSA) is a process by which the live video fluoroscopy images are used to create a permanent set of images that can be reviewed. Iodinated x-ray dye is injected through a thin long tube called a catheter that is inserted into the body's blood vessels. A rapid series of fluoroscopic images is obtained as the x-ray dye flows through the blood vessels. A computer then subtracts out all the bony structures. The resultant series of images represent only the vascular structures of the brain.



**DIGITAL STILL IMAGE WITHOUT SUBTRACTION**



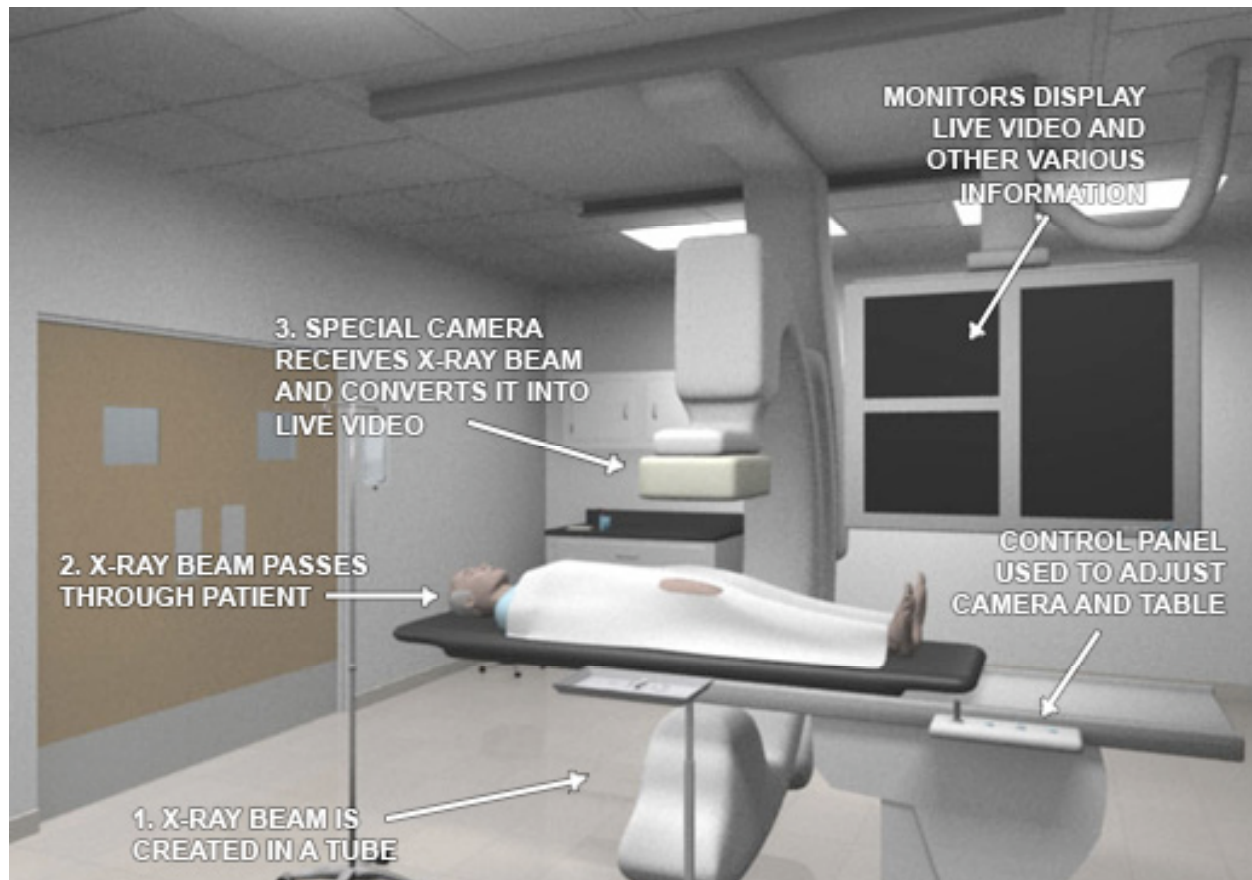
**DIGITAL SUBTRACTION STILL IMAGE WITH BONE SUBTRACTION SHOWING ONLY THE BLOOD VESSELS OF THE BRAIN**

## FLUOROSCOPY

---

Fluoroscopy is live x-ray imaging that allows visualization of bony structures. This is created as a continuous beam of x-rays is allowed to penetrate the body. An x-ray camera then receives the attenuated beams to create a live video image. Metallic objects such as coils and an x-ray dye containing iodine can also be visualized in real time. Soft tissues such as blood vessels of the body cannot be visualized with fluoroscopy.

Iodinated contrast is injected through a catheter into the blood vessel for them to be visualized. The contrast is visualized in real time as it flows from through the brain.



A TYPICAL FLUOROSCOPY SETUP

## IODINATED CONTRAST

---

An X-ray beam is rotated around the head to create an image slice of the brain, called "computerized tomography". Sometimes iodinated contrast is administered through a vein in the arm. This dye flows throughout the body and is imaged once it reaches the brain. Iodinated contrast, like bone, absorbs energy and will appear on the scan results. Iodine absorbs x-ray energy and, in a liquid form, can be safely introduced into the blood vessels of the body. It appears white on CT and is therefore not given in the initial diagnosis of stroke, as it may prevent detection of blood (since blood also appears white on CT scans).

Iodinated contrast is also used for CT Angiography (CTA) and Digital Subtraction Angiography (DSA). In CTA, the contrast is given through a small vein access site, usually in the arm. Imaging by a CT scanner is not in real time. Sliced images of blood vessels in the brain are used to create a 3 dimensional model by a computer.

In DSA, the contrast is injected through a tube called a catheter that is guided into the arterial blood vessel of the neck from the groin region. There is subsequent real time imaging of the contrast as it flows through the blood vessels, using what is referred to as fluoroscopy. This will be discussed in greater detail further on.

## STROKE

---

- A stroke is a generic term that describes an acute onset of a neurologic deficit.
- Hemorrhagic and Ischemic are the two main categories of stroke types, each requiring different types of treatment.
- If left untreated, strokes can lead to severe and irreparable neurological damage. In many cases, even death.

## STROKE DIAGNOSTIC IMAGING TESTS

---

- Computerized Tomography (CT) of the Brain w/o Iodinated Contrast – especially useful for differentiating between ischemic and hemorrhagic strokes.
- Magnetic Resonance Imaging (MRI) of the brain
- Computerized Tomographic Angiography (CTA) of the Brain w/ Iodinated Contrast
- Magnetic Resonance Angiography (MRA)
- Computerized Brain Perfusion Imaging (CTP)
- Conventional Catheter Brain Angiography w/ Digital Subtraction (DSA)

## STROKE RISK FACTORS

---

### Ischemic Stroke

- High blood pressure
- Smoking
- High cholesterol levels, obesity, and physical inactivity
- Irregular heartbeat (called "atrial fibrillation")
- Diabetes
- Prior stroke
- African-American men and women have a significantly increased risk of stroke compared to Caucasians and Hispanics

### Hemorrhagic Stroke

- Head trauma
- Smoking
- Blood-thinning medication
- Hypertension
- Brain blood vessel abnormalities such as aneurysms
- Family history of aneurysms or other brain vascular anomalies

## STROKE SYMPTOMS

---

- Sudden numbness or weakness of face, leg or arm, especially on one side of the body
- Sudden confusion or trouble speaking and/or understanding speech
- Sudden dimness or loss of vision in one or both eyes
- Sudden severe headache with no known cause, often described as the "worst headache of your life". This is typical of a type of hemorrhagic stroke called a Subarachnoid Hemorrhage (SAH).
- Sudden dizziness, loss of balance or unsteadiness

Again, these are just possible warning signs of a stroke. An individual exhibiting any one of these conditions does not necessarily indicate that he or she is having a stroke. However, these symptoms do indicate a possible medical emergency, stroke-related or not. It is best to seek professional medical help immediately to avoid any further (and potentially, life-threatening) complications.

## STROKE GRADING SYSTEMS

---

When a patient is suspected of having a stroke, there are a number of clinical "grading systems" used to indicate the severity of the stroke. Most of these systems involve the doctor performing various tests that assess comprehension, speech, motor skills, etc. The most commonly used grading systems are the Glasgow Outcome Scale, Hunt & Hess Scale, and the NIH (National Institute of Health) Stroke Scale.

In this simulation, we will be using the Hunt and Hess Scale:

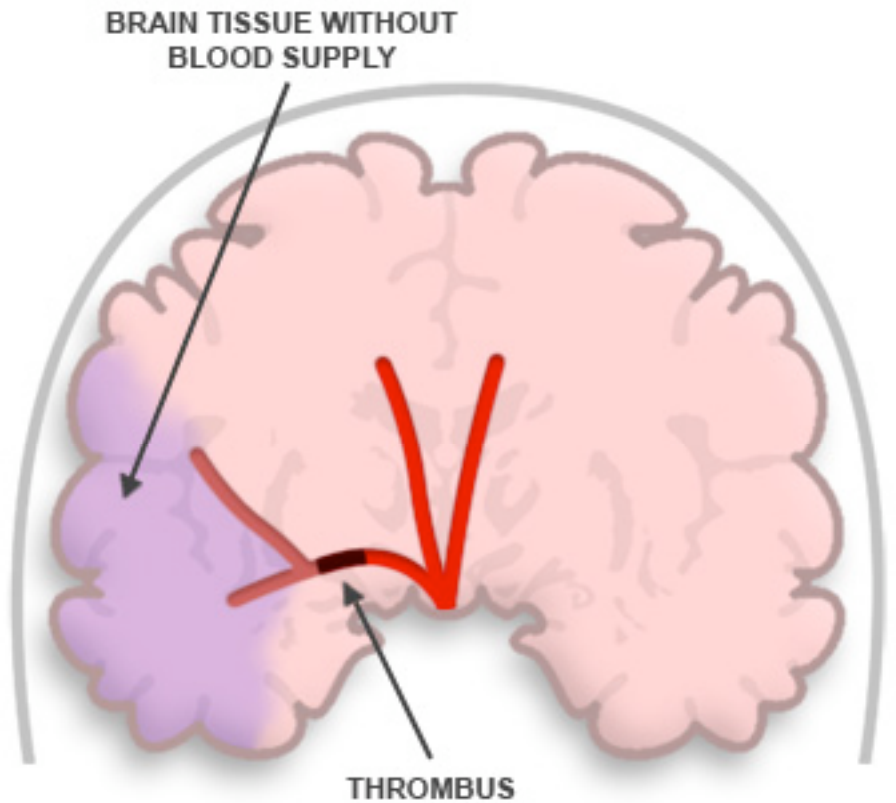
- Grade 0: Asymptomatic
- Grade 1: Mildly symptomatic with headache. Patient Alert.
- Grade 2: Severe headache associated with neck stiffness. Patient alert.
- Grade 3: Severe headache. Patient drowsy/sleepy or confused. May have mild weakness of limbs.
- Grade 4: Patient stuporous. Moderate to severe weakness of limbs on one side.
- Grade 5: Comatose. Unresponsive.

## TYPES OF STROKE

---

### Ischemic Stroke

An ischemic stroke refers to an event where blood supply to portions of the brain is reduced or restricted, often by a blood clot, called a thrombus.



### ISCHEMIC STROKE

ILLUSTRATION OF AN ISCHEMIC STROKE

## Hemorrhagic Stroke

A hemorrhagic stroke is a bleed within the brain. This can occur within membranes that line the surface of the brain, called a **subarachnoid hemorrhage**. It can occur within the brain substance, called an **intra-cerebral hemorrhage**. It can also occur between the spaces of the skull and the brain, called a **subdural** or **epidural hematoma**.

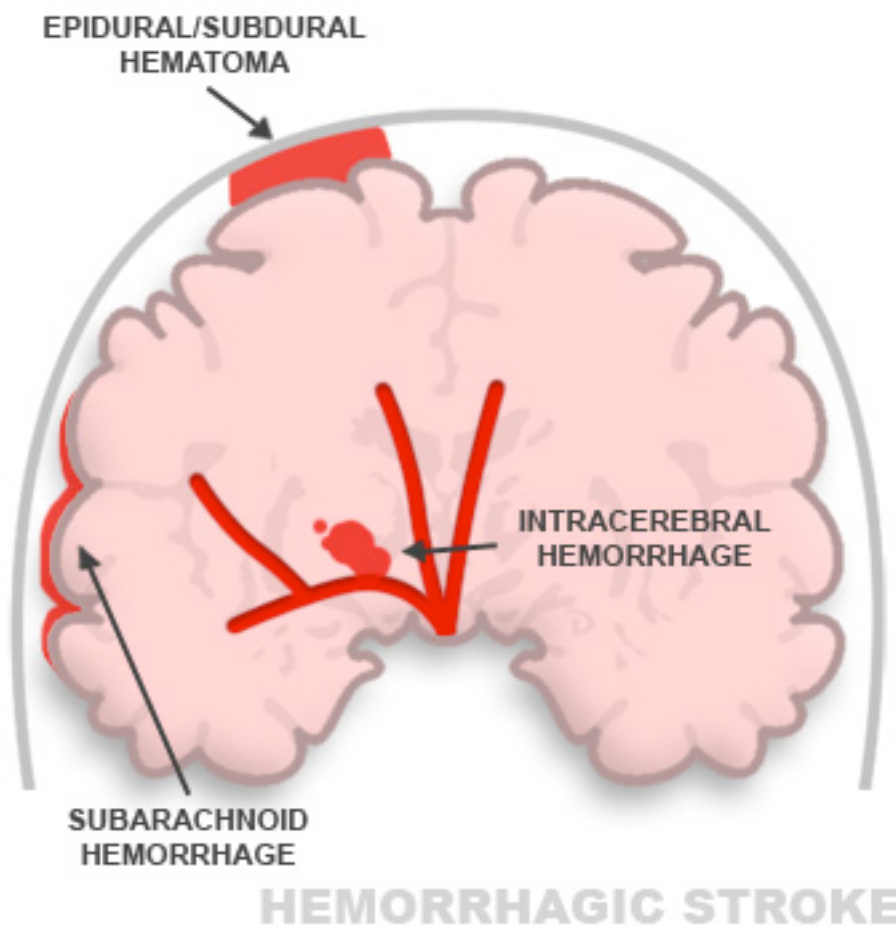


ILLUSTRATION OF A HEMORRHAGIC STROKE

## WORKING PROJECTION


---

The fluoroscopy machine is positioned so that the aneurysm neck is clearly visualized. That way, coils are delivered in the aneurysm cavity and not within the blood vessel of the brain. 3D images help in identifying the correct working projection.

Example of a Working Projection



**CLEAR VIEW OF ANEURYSM**



**ANEURYSM OBSCURED BY ARTERY**

## X-RAYS

---

X-rays are created as excess energy is released from an atom after it is penetrated by an electron beam. The penetrating electron beam displaces orbiting electrons, creating an excited atom that relaxes once the energy is released. This energy is passed through a patient and is deposited on a film to create an image, much like a camera does.

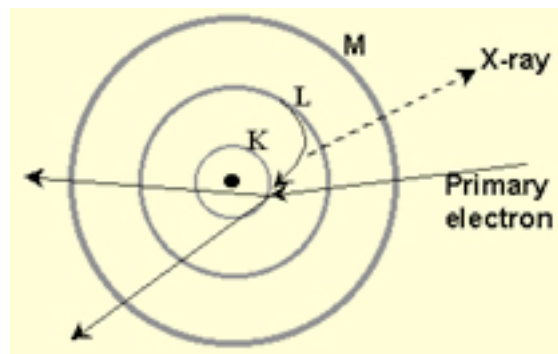
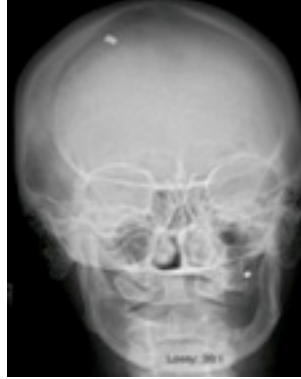

DIAGRAM OF X-RAY

Certain tissues, such as bone, absorb more energy than others. The unabsorbed beam of x-ray energy emerging from the body darkens the



receptive film. The contrast of white (absorbed energy) and black (transmitted energy) creates the x-ray image. X-rays are used in computerized tomography (CT) and computerized tomographic angiography (CTA) as well as in digital subtraction angiography (DSA). DSA will be discussed in later sections.



SKULL X-RAY RESULTS

Copyright © 2008 The Mind Project®. All rights reserved. | Contact: dlanders@ilstu.edu